



PRESENTING CLINICAL SIGNS

DATE History: Recheck DMVD. Asymptomatic.

ECHOCARDIOGRAPHIC FINDINGS

5/6/22 2D, M-mode, Doppler study. This exam is compared to the one performed 11/2/21.

PERFORMED BY:

Dr. Meredith Swart

INTERPRETED BY

Keith Blass, DVM,
MS, DACVIM
(Cardiology)

Left atrial size is normal. The mitral valve leaflets are mildly thickened and exhibit systolic prolapse. There is Doppler evidence of mitral regurgitation present. Left ventricular dimensions are normal. Left ventricular systolic function is mildly hyperdynamic. The aorta and aortic valve appear normal, though trace aortic insufficiency is present. Right atrial and right ventricular dimensions are normal. The tricuspid valve appears normal. The pulmonary artery and pulmonic valve are normal. No pericardial effusion or cardiac masses are seen.

LA - 21.6 mm (prev. 20.0 mm)
LVIDd - 22.5 mm (prev. 19.6 mm)
LVIDs - 12.8 mm (prev. 10.3 mm)
FS - 43% (prev. 47%)
LVOT - 1.84 m/s (prev. 1.60 m/s)
RVOT - 0.98 m/s (prev. 0.79 m/s)

PATIENT

Winnie Cook

ASSESSMENT/RECOMMENDATIONS

Degenerative mitral valve disease

SPECIES

Canine

This examination demonstrates very mild progression of Winnie's mitral valve disease over the past 6 months. While very mild progression has occurred, Winnie still does not have secondary dilation of either of her left heart chambers. As such, her mitral valve disease still appears to be well-compensated, and Winnie's current risk for the development of clinical signs secondary to it, such as coughing, exercise intolerance, syncope, and labored breathing, still appears to be low.

BREED

Shih Tz Mix

No therapy is recommended at this stage of disease.

A recheck echocardiogram is recommended in 6 months to monitor for disease progression.

SEX

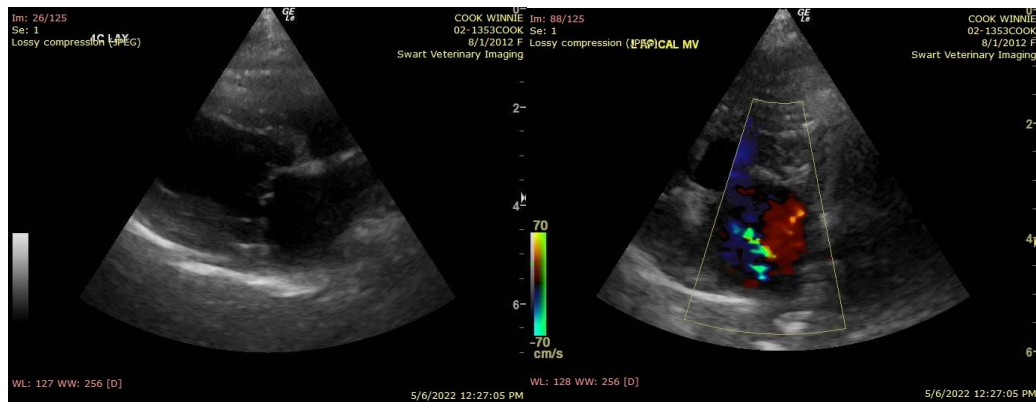
FS

AGE

9 y

WEIGHT

8.76 lb



HOSPITAL NAME

Swart Veterinary
Imaging

REFERRING VET

Dr. Swart



DATE

5/6/22

The information and recommendations provided are based on the images presented by the referring veterinarian. No evaluation can be communicated regarding pathology that was not visible in the image/video clips provided.

PERFORMED BY:

Thank you for this referral. If the clinical or image interpretation does not parallel your findings or if I can be of any further assistance please contact me.

Dr. Meredith Swart

INTERPRETED BY

Keith Blass, DVM, MS, DACVIM (Cardiology)
KeithBlass@gmail.com
631-804-5754

Keith Blass, DVM,
MS, DACVIM
(Cardiology)

PATIENT

Winnie Cook

SPECIES

Canine

BREED

Shih Tz Mix

SEX

FS

AGE

9 y

WEIGHT

8.76 lb

HOSPITAL NAME

Swart Veterinary
Imaging

REFERRING VET

Dr. Swart